

The American Journal of Sports Medicine

<http://ajs.sagepub.com/>

Novel Arthroscopic Classification of Osteochondritis Dissecans of the Knee: A Multicenter Reliability Study

James L. Carey, Eric J. Wall, Nathan L. Grimm, Theodore J. Ganley, Eric W. Edmonds, Allen F. Anderson, John Polousky, M. Lucas Murnaghan, Carl W. Nissen, Jennifer Weiss, Roger M. Lyon, Henry G. Chambers and The Research in Osteochondritis of the Knee (ROCK) Group

Am J Sports Med 2016 44: 1694 originally published online April 6, 2016

DOI: 10.1177/0363546516637175

The online version of this article can be found at:

<http://ajs.sagepub.com/content/44/7/1694>

Published by:



<http://www.sagepublications.com>

On behalf of:

American Orthopaedic Society for Sports Medicine



Additional services and information for *The American Journal of Sports Medicine* can be found at:

Email Alerts: <http://ajs.sagepub.com/cgi/alerts>

Subscriptions: <http://ajs.sagepub.com/subscriptions>

Reprints: <http://www.sagepub.com/journalsReprints.nav>

Permissions: <http://www.sagepub.com/journalsPermissions.nav>

>> [Version of Record](#) - Jul 1, 2016

[OnlineFirst Version of Record](#) - Apr 6, 2016

[What is This?](#)

Novel Arthroscopic Classification of Osteochondritis Dissecans of the Knee

A Multicenter Reliability Study

James L. Carey,^{*†} MD, MPH, Eric J. Wall,[‡] MD, Nathan L. Grimm,[§] MD, Theodore J. Ganley,^{||} MD, Eric W. Edmonds,[¶] MD, Allen F. Anderson,[#] MD, John Polousky,^{**} MD, M. Lucas Murnaghan,^{††} MD, Carl W. Nissen,^{‡‡} MD, Jennifer Weiss,^{§§} MD, Roger M. Lyon,^{||||} MD, Henry G. Chambers,^{¶¶} MD, and The Research in OsteoChondritis of the Knee (ROCK) Group^{¶¶¶}

Investigation performed at Perelman School of Medicine at the University of Pennsylvania, Philadelphia, Pennsylvania, USA

Background: Several systems have been proposed for classifying osteochondritis dissecans (OCD) of the knee during surgical evaluation. No single classification includes mutually exclusive categories that capture all of the salient features of stability, chondral fissuring, and fragment detachment. Furthermore, no study has assessed the reliability of these classification systems.

Purpose: To determine the intra- and interobserver reliability of a novel, comprehensive arthroscopic classification system with mutually exclusive OCD lesion types.

Study Design: Cohort study (diagnosis); Level of evidence, 3.

Methods: The Research in OsteoChondritis of the Knee (ROCK) study group developed a classification system for arthroscopic evaluation of OCD of the knee that includes 6 arthroscopic categories—3 immobile types and 3 mobile types. To optimize comprehensibility and applicability, each was developed with a memorable name, a brief description, a line diagram corresponding to the archetypal arthroscopic appearance, and an arthroscopic photograph depicting this archetype. Thirty representative arthroscopic videos were evaluated by 10 orthopaedic surgeon raters, who classified each lesion. After 4 weeks, the raters again classified the OCD lesions depicted in the 30 videos in a new, randomly selected order. Reliability was assessed via the intraclass correlation coefficient (ICC).

Results: The interobserver reliability of this novel arthroscopy classification was estimated by an ICC of 0.94 (95% CI, 0.91-0.97) for the first round and 0.95 (95% CI, 0.93-0.98) for the second round. According to the standards for the magnitude of the reliability coefficient of Altman, these ICCs indicate that interobserver reliability was very good. The intraobserver reliability was estimated by an ICC of 0.96 (95% CI, 0.95-0.97), which indicates that the intraobserver reliability was similarly very good.

Conclusion: The ROCK OCD knee arthroscopy classification system demonstrated excellent intra- and interobserver reliability. In light of this reliability, this classification system may be used clinically and to facilitate future research, including multicenter studies for OCD.

Keywords: osteochondritis dissecans; arthroscopy; classification

Osteochondritis dissecans (OCD) was initially described as a spontaneous condition that brings about detached pieces of the articular surface without any other considerable damage to the joint.¹⁹ OCD has been recently defined as a focal, idiopathic alteration of subchondral bone with potential for instability and disruption of adjacent articular cartilage that may result in premature (early secondary) osteoarthritis.¹²

Many factors have been described that influence selection of optimal treatment of OCD lesions in the knee. The following factors have been listed as common branch points in treatment algorithms for the condition: presence or absence of symptoms, skeletal maturity, size of lesion, stability of lesion, fissuring about margins of lesion, degree of detachment, adequacy of subchondral bone, and salvageability of loose fragments.^{2,4-6,8-10,14,23} History, physical examination, and imaging studies help to characterize many of these features.

Ultimately, arthroscopic evaluation provides the best assessment for the following subset of features of the OCD lesion: stability, fissuring, and detachment. Several

systems have been proposed for classifying OCD of the knee during surgical evaluation.^{3,7,11,16,18,21,22} However, a recent review of these arthroscopic classification systems highlighted that no single one includes all features.¹⁷ That is, an OCD lesion cannot be comprehensively classified through any one system. Furthermore, no study assessed the reliability of any of these classification systems. A reliable arthroscopic classification system would not only have clinical utility in providing surgeons with a common language when addressing this complex entity but also permit the future study of treatments for OCD lesions with different features.

Consequently, the Research in OsteoChondritis of the Knee (ROCK) study group described a novel, comprehensive arthroscopic classification with mutually exclusive OCD lesion types that were easily memorable and identifiable. The purpose of this study was to test the hypothesis that this classification system would yield acceptable intra- and interobserver reliability.

METHODS

Description of Novel Arthroscopic Classification System

The ROCK study group developed a classification system for arthroscopic evaluation of OCD of the knee. The system involved 6 arthroscopic categories (Figure 1). To optimize comprehensibility and applicability, each category or type was described with a memorable name (eg, “trap door”), a brief description, a line diagram corresponding to the memorable name, an illustration corresponding to the archetypal arthroscopic appearance, and an arthroscopic photograph depicting this archetype.

Study Design

Sample size estimates for raters and subjects were performed a priori through the principles described by Giraudeau and Mary.¹⁵ Specifically, in the setting of 6 categories, 30 representative arthroscopic videos were planned to be evaluated by 10 orthopaedic surgeon raters. Specific arthroscopic videos were selected by 3 other surgeons (J.L.C., K.G.S., E.J.W.) to represent the spectrum of disease, including 3 to 7 videos for each category.

Raters did not participate in the video case selection or preparation. Raters did participate in a training module (including archetypal arthroscopic photos, videos, and line drawings) before rating the first round of videos. The training module used an entirely separate set of images, without any overlap with the set of study images. Raters were also provided with a printed page with some tips for distinguishing borderline cases (Table 1).

The videos were placed in a random order as a single movie with 30 chapters on a DVD, which did permit repeated playback of each arthroscopic video. The 30 arthroscopic videos were rated by each of the 10 raters, in a blind fashion. After 4 weeks, the raters were provided with a second DVD, with the 30 videos in a new, randomly selected order. These videos were then blindly rated again by each reviewer.

Statistical Analyses

Intra- and interobserver reliability was assessed through the intraclass correlation coefficient (ICC), which, when applied to categorical data, is exactly equivalent to the weighted kappa with quadratic weighting.¹³ Calculations were performed with Stata Statistical Software (Release 10; Stata-Corp). The magnitude of the reliability coefficient was interpreted according to the “standard” initially proposed by Landis and Koch²⁰ and then slightly adapted by Altman¹ as follows: 0.00 to 0.20, poor; 0.21 to 0.40, fair; 0.41 to 0.60, moderate; 0.61 to 0.80, good; and 0.81 to 1.00, very good.

RESULTS

The interobserver reliability of this novel arthroscopy classification was estimated by an ICC of 0.94 (95% CI, 0.91-0.97) for the first round and 0.95 (95% CI, 0.93-0.98) for the second round. According to the standards for the magnitude of the reliability coefficient of Altman,¹ these ICCs indicate that interobserver reliability was very good.

The intraobserver reliability was estimated by an ICC of 0.96 (95% CI, 0.95-0.97), which indicates that the intraobserver reliability was similarly very good.

In the 4 cases of perfect agreement, 3 were classified as “craters” and 1 as a “wrinkle in the rug.” In the 26 cases with some disagreement, 20 cases involved classification into 2 adjacent types (“locked door” and “trap door”), 4

*Address correspondence to James L. Carey, MD, MPH, Penn Sports Medicine Center, Weightman Hall, 235 South 33rd Street, Philadelphia, PA 19104, USA (email: james.carey@uphs.upenn.edu).

†Perelman School of Medicine at the University of Pennsylvania, Philadelphia, Pennsylvania, USA.

‡Cincinnati Children’s Hospital Medical Center, Cincinnati, Ohio, USA.

§Duke University, Durham, North Carolina, USA.

||The Children’s Hospital of Philadelphia, Philadelphia, Pennsylvania, USA.

*Rady Children’s Hospital–San Diego, San Diego, California, USA.

#Tennessee Orthopaedic Alliance, Nashville, Tennessee, USA.

**Rocky Mountain Youth Sports Medicine Institute, Centennial, Colorado, USA.

††The Hospital for Sick Children, Toronto, Ontario, Canada.

‡‡Connecticut Children’s Medical Center, Farmington, Connecticut, USA.

§§Kaiser Permanente Southern California, Los Angeles, California, USA.

|||Medical College of Wisconsin, Milwaukee, Wisconsin, USA.

*†††All members are listed in the Contributing Authors section at the end of this article.

The authors declared that they have no conflicts of interest in the authorship and publication of this contribution.

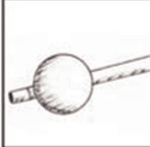

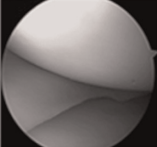


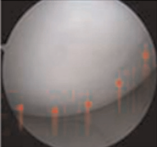


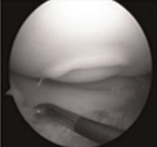


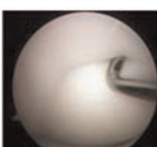


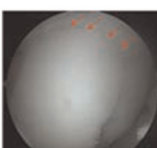


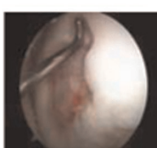
	Type and Description	Diagrams
Immobile Lesions	<p>Cue ball: No abnormality detectable arthroscopically.</p>	  
	<p>Shadow: Cartilage is intact and subtly demarcated (possibly under low light).</p>	  
	<p>Wrinkle in the rug: Cartilage is demarcated with a fissure, buckle, and/or wrinkle.</p>	  
Mobile Lesions	<p>Locked door: Cartilage fissuring at periphery, <i>unable</i> to hinge open.</p>	  
	<p>Trap door: Cartilage fissuring at periphery, <i>able</i> to hinge open.</p>	  
	<p>Crater: Exposed subchondral bone defect.</p>	  

Figure 1. The Research in OsteoChondritis of the Knee (ROCK) study group arthroscopic classification system for osteochochondritis dissecans lesions.

TABLE 1
Distinguishing Borderline Lesion Types

Type in Question	Instruction
“Cue ball” or “shadow”	If you can detect any abnormality, <i>then choose “shadow”</i>
“Shadow” or “wrinkle in the rug”	If a small car (with 3-mm wheels) driving over the boundary would feel a speed bump (up and down) or speed dip (down and up), <i>then choose “wrinkle in the rug”</i>
“Wrinkle in the rug” or “locked door”	If fissuring is completely down to bone, <i>then choose “locked door”</i>
“Locked door” or “trap door”	If you can see any part of the “room” behind the door, <i>then choose “trap door”</i>
“Trap door” or “crater”	If the progeny is observed to have no functional hinge, <i>then choose “crater”</i>

cases into 3 adjacent types (“trap door,” “locked door,” and “crater”), and 2 cases into nonadjacent types (“locked door” and “crater”).

With respect to mobile and immobile, 6 cases involved classification into the adjacent types of “wrinkle in the rug” and “locked door,” defined as immobile and mobile, respectively.

DISCUSSION

To our knowledge, there has not been any previous study of reliability for any arthroscopic classification system of OCD. After the extraction of important features from previously published treatment algorithms^{2,4-6,8-10,14,23} and arthroscopic classification systems,^{3,7,11,16,18,22} as well as

entertaining additional features from expert consensus, the novel ROCK arthroscopy classification was created to include these important features within mutually exclusive OCD lesion types. In the current study, this new classification system was found to have very good reliability.

Language and Definitions

To maximize reliability while maintaining usefulness, the language of this novel classification system was chosen carefully. Specifically, other published arthroscopy classifications have used “stable”^{3,18} and “not displaceable”^{11,21,22} to describe the mechanical integrity of the subchondral bone of fragments that are in place. One classification¹⁸ also used “fragment mobile with compression,” which seemed to clarify this point. Therefore, the current classification system dichotomizes on the basis of “mobile” and “immobile” lesions because this most closely describes the feature that is actually observed during arthroscopy. Specifically, mobility describes whether the progeny fragment can be observed to move with probing, with respect to the surrounding cartilage and bone.

In addition, other published arthroscopy classifications have used “discontinuity,”¹² “fissure,”^{7,21} “breach,”^{11,22} and “separation”¹⁶ to describe the cartilage integrity. These terms are related to the descriptors “in situ,”¹⁸ “dislocated,”³ “detached,”^{7,16,21,22} and “loose,”^{3,7,11,16,21,22} which describe the position of the fragment with respect to its normal position. While these terms describe the features observed during arthroscopy, the current classification system combines the cartilage integrity and fragment position into a logical and graduated continuum from “cue ball” to “crater.”

Of note, salvageability was purposefully omitted. A salvageable fragment can be saved. Features typically associated with salvageable fragments include the following: the fragment contains bone on deep surface, the fragment is one piece, and the fragment contains undamaged articular cartilage. An OCD lesion best classified by any of the 6 types presented in the current arthroscopy classification may be a salvageable lesion; that is, even a “crater” with a congruent, nonfragmented loose body may be salvageable. The salvageability of an OCD lesion fragment is often a complex decision that involves arthroscopic evaluation as well as review of skeletal maturity, prior treatments, radiographic and magnetic resonance imaging findings of the lesion, and direct inspection and manual palpation of the fragment.

Limitations

There are several potential limitations of the current study. First, the observer of a video does not experience what an operating surgeon experiences, especially with respect to tactile feedback from the probe. Tactile feedback may have enhanced the ability to distinguish between mobile and immobile types—specifically between “wrinkle in the rug” and “locked door.” Second, orthopaedic surgeon raters were members of a research study group focused on OCD and may not be representative of all physicians that treat these lesions. The training module may have enhanced their classification skills further. Third, the

arthroscopic videos were selected by a few surgeons to represent the spectrum of disease that they have observed, but perhaps there are other types of OCD lesions that were not represented. That is, surgeons may discover that certain rare lesions cannot be classified by this system and additional types may need to be added. Further testing of this classification system by surgeons with varying age, experience, and training may lead to further refinements.

CONCLUSION

The ROCK OCD knee arthroscopy classification system demonstrated very good reliability. In light of this reliability, this classification system may be used to facilitate a common language by surgeons who encounter or address such lesions intraoperatively, as well as to facilitate future research, including multicenter studies for OCD.

CONTRIBUTING AUTHORS

Rick W. Wright, MD (Washington University, St Louis, Missouri, USA); Benton E. Heyworth, MD (Children’s Hospital Boston, Boston, Massachusetts, USA); Lars Peterson, MD, PhD (Sahlgrenska Academy, University of Gothenburg, Gothenburg, Sweden); Gregory D. Myer, PhD (Cincinnati Children’s Hospital Medical Center, Cincinnati, Ohio, USA); and Kevin G. Shea, MD (St Luke’s Health System, Boise, Idaho, USA).

REFERENCES

1. Altman DG. *Practical Statistics for Medical Research*. London, UK: Chapman & Hall; 1991.
2. Anderson AF, Anderson CN. Management of osteochondritis dissecans of the knee. *Tech Knee Surg*. 2005;4(1):23-25.
3. Brittberg M, Winalski CS. Evaluation of cartilage injuries and repair. *J Bone Joint Surg Am*. 2003;85(suppl 2):58-69.
4. Cahill B. Treatment of juvenile osteochondritis dissecans and osteochondritis dissecans of the knee. *Clin Sports Med*. 1985;4(2):367-384.
5. Cahill BR. Osteochondritis dissecans of the knee: treatment of juvenile and adult forms. *J Am Acad Orthop Surg*. 1995;3(4):237-247.
6. Cain EL, Clancy WG. Treatment algorithm for osteochondral injuries of the knee. *Clin Sports Med*. 2001;20(2):321-342.
7. Chen CH, Liu YS, Chou PH, Hsieh CC, Wang CK. MR grading system of osteochondritis dissecans lesions: comparison with arthroscopy. *Eur J Radiol*. 2013;82(3):518-525.
8. Clanton TO, DeLee JC. Osteochondritis dissecans: history, pathophysiology and current treatment concepts. *Clin Orthop Relat Res*. 1982;167:50-64.
9. Crawford DC, Safran MR. Osteochondritis dissecans of the knee. *J Am Acad Orthop Surg*. 2006;14(2):90-100.
10. Dettlerline AJ, Goldstein JL, Rue JP, Bach BR Jr. Evaluation and treatment of osteochondritis dissecans lesions of the knee. *J Knee Surg*. 2008;21(2):106-115.
11. Dipaola JD, Nelson DW, Colville MR. Characterizing osteochondral lesions by magnetic resonance imaging. *Arthroscopy*. 1991;7(1):101-104.
12. Edmonds EW, Shea KG. Osteochondritis dissecans: editorial comment. *Clin Orthop Relat Res*. 2013;471(4):1105-1106.

13. Fleiss JL, Cohen J. The equivalence of weighted kappa and the intraclass correlation coefficient as measure of reliability. *Educ Psychol Measurement*. 1973;33:613-619.
14. Flynn JM, Kocher MS, Ganley TJ. Osteochondritis dissecans of the knee. *J Pediatr Orthop*. 2004;24(4):434-443.
15. Giraudeau B, Mary JY. Planning a reproducibility study: how many subjects and how many replicates per subject for an expected width of the 95 per cent confidence interval of the intraclass correlation coefficient. *Stat Med*. 2001;20(21):3205-3214.
16. Guhl JF. Arthroscopic treatment of osteochondritis dissecans: preliminary report. *Orthop Clin North Am*. 1979;10(3):671-683.
17. Jacobs JC Jr, Archibald-Seiffer N, Grimm NL, Carey JL, Shea KG. A review of arthroscopic classification systems for osteochondritis dissecans of the knee. *Clin Sports Med*. 2014;33(2):189-197.
18. Johnson LL, Uitvlugt G, Austin MD, Detrisac DA, Johnson C. Osteochondritis dissecans of the knee: arthroscopic compression screw fixation. *Arthroscopy*. 1990;6(3):179-189.
19. König F. Über freie Körper in den Gelenken [translated by Drs Richard A. Brand and Christian-Dominik Peterlein. *Clin Orthop Rel Res*. 2013;471:1107-1115]. *Dtsch Z Klin Chir*. 1887;27:90-109.
20. Landis JR, Koch GG. The measurement of observer agreement for categorical data. *Biometrics*. 1977;33(1):159-174.
21. Nelson DW, DiPaola J, Colville M, Schmidgall J. Osteochondritis dissecans of the talus and knee: prospective comparison of MR and arthroscopic classifications. *J Comput Assist Tomogr*. 1990;14(5):804-808.
22. O'Connor MA, Palaniappan M, Khan N, Bruce CE. Osteochondritis dissecans of the knee in children: a comparison of MRI and arthroscopic findings. *J Bone Joint Surg Br*. 2002;84(2):258-262.
23. Pill SG, Ganley TJ, Flynn JM, Milam RA, King PJ, Gregg JR. Osteochondritis dissecans of the knee: experiences at the Children's Hospital of Philadelphia and a review of literature. *The University of Pennsylvania Orthopaedic Journal*. 2001;14:25-33.

For reprints and permission queries, please visit SAGE's Web site at <http://www.sagepub.com/journalsPermissions.nav>.